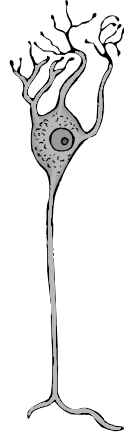

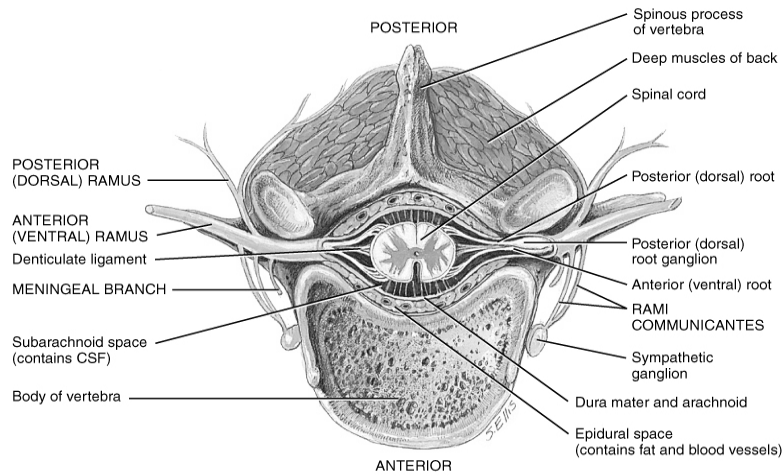
# Bio& 241 A&P

## Unit 4 Lecture 4



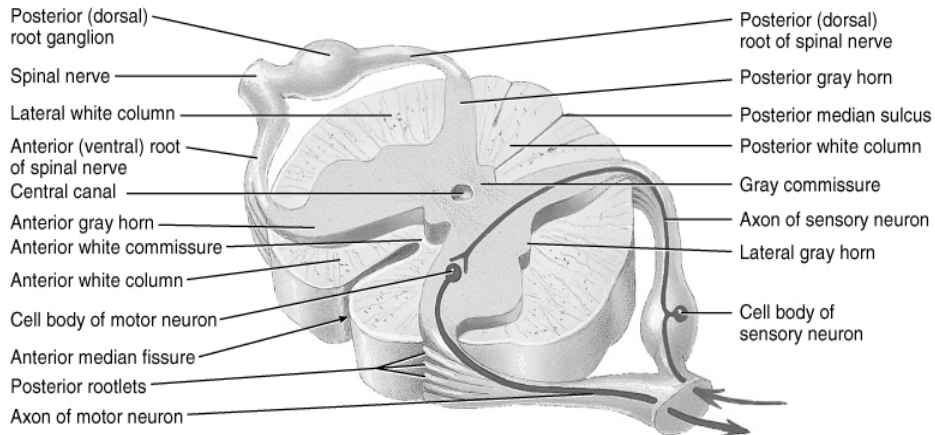
Granule Cell

## Position of the Spinal Cord in relationship to the Vertebral Foramen



© John Wiley & Sons, Inc.

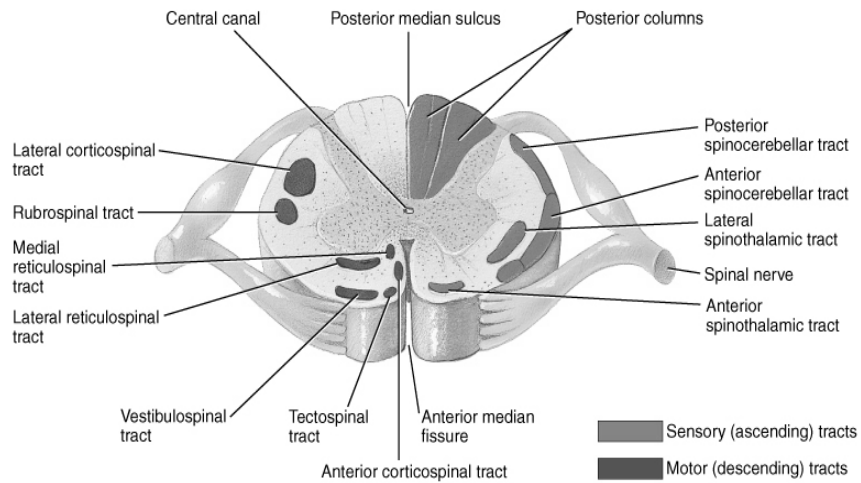
## Gross Anatomy of the Spinal Cord



(a) Transverse section of the thoracic spinal cord

© John Wiley & Sons, Inc.

## Ascending and Descending Tracts of the Spinal Cord



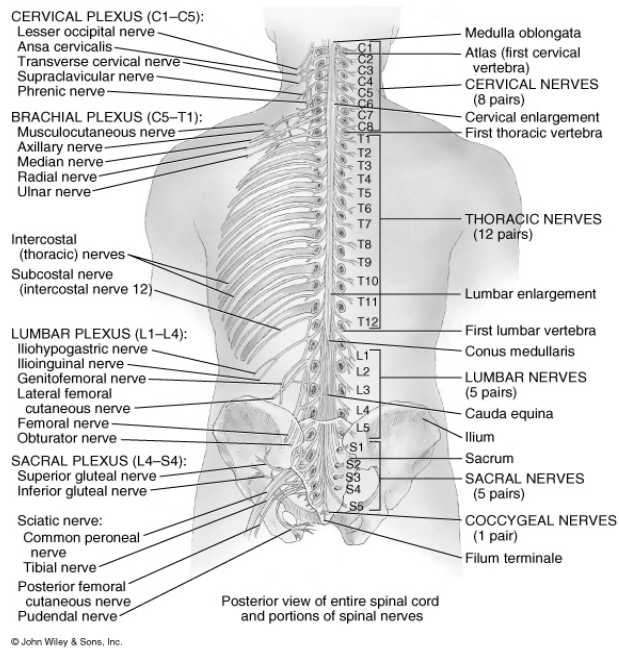
© John Wiley & Sons, Inc.

## Spinal Nerves

- **Cervical nerves**                    **8 pairs**
- **Thoracic Nerves**                **12 pairs**
- **Lumbar Nerves**                 **5 pairs**
- **Sacral Nerves**                  **5 pairs**
- **Coccygeal Nerves**            **1 pair**
  
- **Total**                                **31 pairs**

## Spinal Plexuses and Nerves

- **Cervical Plexus (C1-C5)**  
     **Phrenic nerve**
- **Brachial Plexus (C5-T1)**  
     **Axillary nerve, Radial nerve, Ulnar nerve**
- **Lumbar Plexus (L1-L4)**  
     **Femoral nerve, Genitofemoral nerve**
- **Sacral Plexus (L4-S4)**  
     **Sciatic nerve, Pudendal nerve**



## Spinal Nerves from the Cervical and Brachial plexuses

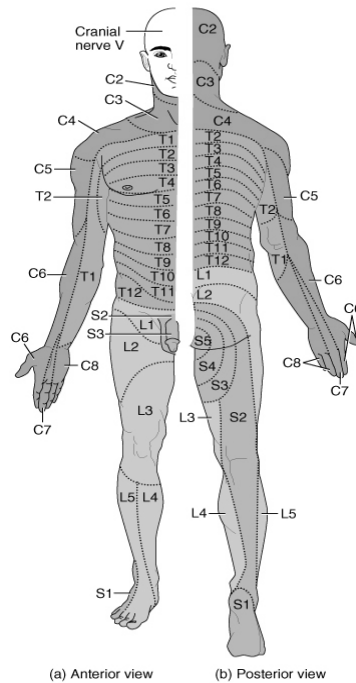
Nerve	Distribution
Phrenic	Diaphragm
Axillary	Deltoid, teres minor
Radial	Triceps brachii, extensor of the forearms
Ulnar	Flexor carpi ulnaris, skin of the medial side of hand, 5 <sup>th</sup> finger, medial half of 4 <sup>th</sup> finger

## Spinal Nerves from the Lumbar plexus

Nerve	Distribution
Genitofemoral	Cremaster muscle, skin over middle anterior surface of the thigh, scrotum and Labia majora
Femoral	Flexor muscles of thigh, leg extensor muscles, skin over anterior and medial thigh, medial leg and foot

## Spinal Nerves from the Sacral plexus

Nerve	Distribution
Sciatic	Combination of two nerves, tibial and common peroneal, innervates most of lower leg.
Pudendal	Muscle of the perineum, skin of the penis and scrotum, clitoris, labial majora, labial minora, and vagina



© John Wiley & Sons, Inc.

# Review of Cranial Nerves

